



# Recombinant Factor VIIa in a Case of Pontine Hemorrhage

S Meenakshi-Sundaram<sup>\*\*\*</sup>, TC Vijay Anand<sup>\*\*\*</sup>, G Suriyakumar<sup>\*</sup>, Rohini Sridhar<sup>\*\*</sup>,  
S Sundararajan<sup>\*\*\*</sup>, Bharathi Sundar<sup>\*\*\*</sup>

## Abstract

A 59-year-old lady presented with hypertensive hemorrhage involving the pons. Since she presented within 3 hours of onset of the stroke, recombinant factor VIIa was administered. From a state of altered sensorium there was a rapid recovery of consciousness followed by gradual improvement in limb weakness. Serial CT scans of the brain revealed no further expansion of the hematoma. The hematoma progressively resolved. Recombinant factor VIIa could be an attractive therapeutic option in treating hemorrhages at critical sites like brainstem where expansion of hematoma could be fatal. ©

Intracerebral hemorrhage (ICH) has a higher morbidity rate than ischemic stroke.<sup>1</sup> Hemorrhage occurring in the brainstem is associated with even higher morbidity and mortality rates than those occurring at other sites. It has now been well established that hematoma growth occurs following the initial hemorrhagic event and such growth increases the mortality and worsens the neurological outcome.<sup>2</sup> Measures to limit the expansion of the hematoma may thus favorably modify the outcome. We report a patient who presented with pontine hemorrhage and was treated with recombinant factor VIIa (Novoseven).

## CASE REPORT

A 59-year-old lady presented with vomiting followed by altered sensorium since 2 hours. She was a known hypertensive since 10 years and was on losartan (50 mg/d) and hydrochlorothiazide (12.5 mg/d). She was also a known diabetic since 15 years on regular therapy. Examination revealed: Pulse rate: 88/minute, regular; Respiratory rate: 16/minute; BP: 240/140 mm Hg; Temperature: 98.4 °F. Cardiorespiratory and per abdomen examinations were unremarkable. Neurologically she was in altered sensorium, was not arousable to loud call and could move left sided limbs minimally to deep pain. She had left gaze palsy. Pupils were 1.5 mm bilaterally. Hypotonia was noted over the right sided limbs that showed paucity of movements. Stretch reflexes were absent over the right side and brisk over the left side. Plantar response was extensor bilaterally.

Cranial, unenhanced CT scan revealed hyperdense lesion suggestive of hematoma (2.4 x 1.5 x 2.0 cm, approximate volume 3.6 cc, Fig. 1A) in the central pons, extending to the left side with mild effacement of prepontine cisterns. Coagulation profile was normal. Since she presented within 3 hours of onset of stroke, recombinant factor VIIa (2.4 mg intravenously over 5 minutes) was administered. Antihypertensive and antidiabetic drugs were continued. Her sensorium improved rapidly and she could obey commands by day 2. Cranial CT scan done on day 3 did not show any expansion of hematoma (Fig. 1B) and one done on day 7 (Fig. 1C) revealed reduced attenuation of the hyperdensity representing resolving hemorrhage. She could walk with support on day 22 and a repeat CT scan on day 25 (Fig. 1D) revealed total resolution of the hemorrhage.

## DISCUSSION

Following ICH growth of hematoma is known to be an independent predictor of mortality and poor outcome. Causes of the expansion of the hematoma are: continued bleeding from the primary source and mechanical disruption of the surrounding vessels attributable to acute hypertension and a local coagulation defect<sup>3</sup>. Hemostatic therapy offers the advantage of limiting the expansion of the growth, thus improving the outcome. This may be more relevant in the infratentorial compartment where the limitations of space may result in compression and mass effect over vital areas of the brain.

Recombinant human factor VII a (Novoseven) is a hemostatic agent used for treating hemophilia, congenital factor VII deficiency and Glanzman's thrombasthenia.<sup>4</sup> Off-label use of the drug is now well known and it has been used in a variety of other conditions such as factor XI deficiency, Von Willebrand's disease, inherited disorders of

Departments of <sup>\*\*\*</sup>Neurosciences, <sup>\*</sup>Radiology and <sup>\*\*</sup>Hematology, Apollo Speciality Hospitals, Lake View Road, KK Nagar, Madurai, Tamil Nadu, India - 625 020.  
Received : 31.3.2008; Accepted : 30.7.2008

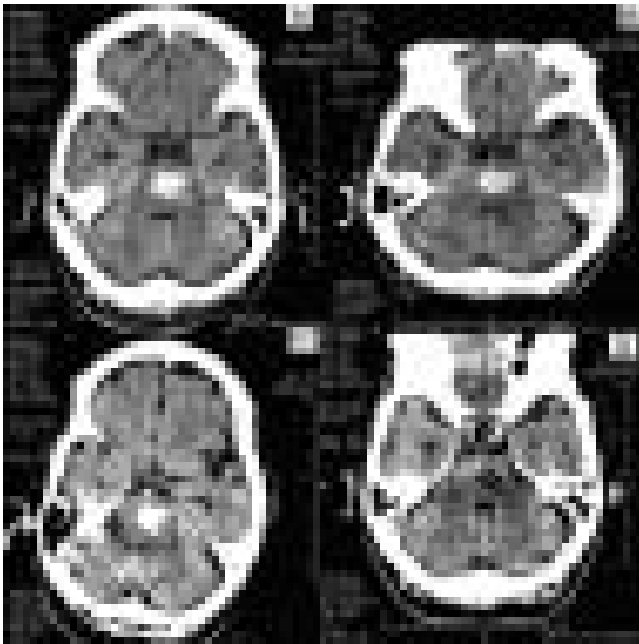


Fig. 1 (A, B, C and D) : Pontine hemorrhage seen on day 1 (Fig A).

Hyperdense lesion suggestive of hematoma (2.4 x 1.5 x 2.0 cm approximate volume 3.6 cc) is noted in the central pons extending to the left side with mild effacement of prepontine cistern. On day 3 (Fig. B) there is no evidence of hematoma expansion (2.4 x 1.4 x 1.8 cm, approximate volume 3.0 cc). There is reduction in the size of hematoma on day 7 (Fig. C), (2.2 x 1.3 x 1.7 cm, approximate volume 2.5 cc). On day 25 cranial CT scan reveals hypodensity in the central pons suggesting complete resolution of the hematoma (Fig. D)

platelet functions like Bernard- Soullier syndrome, warfarin –associated hemorrhage and for reducing post operative blood loss. The drug has shown promise in the management of patients with primary ICH. In a multicenter phase 2 B

trial involving 399 patients, treatment with recombinant factor VIIa was associated with reduced disability or death at 3 months compared to placebo.<sup>5</sup> While use of this agent still remains investigational in ICH, a case may be made to consider its use in patients with hemorrhage in critical areas like brainstem. Our patient recovered rapidly clinically. Radiologically no further worsening of the hematoma size was noted that could have been spontaneous, attributable to BP control alone or to use of rFVII a. The hemorrhage gradually reduced in size subsequently with further clinical improvement. Thus rFVIIa could be an attractive option in the management of brainstem hemorrhage.

#### REFERENCES

1. Flaherty ML, Haverbusch M, Sekar P, et al. Long-term mortality after intracerebral hemorrhage. *Neurology* 2006;66:1182-6.
2. Kazui S, Naritomi H, Yamamoto H, Sawada T, Yamaguchi T. Enlargement of spontaneous intracerebral hemorrhage: incidence and time course. *Stroke* 1996;27:1783-7.
3. Olson JD. Mechanisms of homeostasis: effect on intracerebral hemorrhage. *Stroke* 1993;24:Suppl: 1109-14.
4. Kessler M. New products for managing inhibitors to coagulation factors: a focus on recombinant factor VIIa concentrate. *Curr Opin Hematol* 2000;7:408.
5. Mayer SA, Brun NC, Begtrup K, et al. Recombinant activated factor VII for acute intracerebral hemorrhage. *N Eng J Med* 2005;352:777-85.

#### Announcement

#### UPDACON 2008

7th Annual Conference of Uttar Pradesh Diabetes Association will be held on 1<sup>st</sup> and 2<sup>nd</sup> November, 2008 at Hotel Duke Palace, Mathura (U.P.) it will be hosted by Physician's Forum, Mathura.

For registration and other details, Please contact : Dr. Vipin Kumar, Organising Secretary, Vipin Nursing Home, Krishna Nagar, Mathura - 281004.

Phone : 05465 2420738, 2422938; Fax : 0565-2425215

Email : vipinkdr@yahoo.com; Mobile : 09837088809

#### Announcement

6<sup>th</sup> National Conference of Cardiology, Diabetology, Electrocardiology, Echocardiography and Critical Care. 7<sup>th</sup> and 9<sup>th</sup> November 2008 at Hotel Jehan Numa Palace, Shamla Hills, Bhopal (M.P.)

For details contact : Conference Secretariat : Dr. PC Manoria, E-5/103, Arera Colony, Bhopal M.P. - 462016

Ph. : 91-0755-2422299. Mob. No. : 9893042229; Fax : 91-0755-2532405; E-mail : pmanoria@rediffmail.com